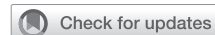

## Aortic valve surgery in children



Edward Buratto, MBBS, PhD,<sup>a,b,c</sup> and Igor E. Konstantinov, MD, PhD, FRACS<sup>a,b,c,d</sup>

The ideal aortic valve surgery in children must result in an unobstructed, competent aortic valve that is also durable and accommodates growth of the child. Intuitively, aortic valve surgery in children must emulate native aortic valve anatomy and physiology as close as possible, preferably using autologous tissues with growth potential. The optimal approach to aortic valve surgery in children is yet to be defined. The purpose of this focused review is to highlight recent key publications on the topic.



Drs Buratto and Konstantinov at the Royal Children's Hospital, Melbourne.

### AORTIC VALVE REPAIR

Aortic valve repair is currently performed in children with increasingly good results.<sup>1</sup> Last year, outstanding results of aortic valve repair in neonates were reported by Vergnat and colleagues<sup>2</sup> in neonates with congenital aortic stenosis treated between 1989 and 2015. Of these patients, 52 underwent surgical aortic valve repair and 51 underwent balloon aortic dilatation. There was similar early mortality (7.8% for ballooning vs 3.9% for repair) and 10-year survival (88% for ballooning vs 94% for surgery,  $P = .25$ ). However, freedom from reoperation was superior in the group undergoing aortic valve repair (66% vs 36%,  $P < .01$ ). Similar results have been reported by Siddiqui and colleagues<sup>3</sup> for neonates and infants. Thus, it appears that the outcomes of aortic valve repair in neonates and infants are superior to those achieved by balloon dilation.

In children aged more than 1 year, the operative mortality for aortic valve repair is 0.4% to 1.8% and freedom from reoperation is approximately 70% at 10 years.<sup>4</sup> d'Udekem and colleagues<sup>5</sup> reported 142 children who underwent aortic valve repairs between 1996 and 2009 at a median age of 9 years. Early mortality was 1.8% in children aged more than 1 year. Freedom from reoperation was 80% at 7 years follow-up. The use of cusp extension was associated with increased risk of reoperation.

From the <sup>a</sup>Department of Cardiac Surgery, Royal Children's Hospital, Melbourne, Australia; <sup>b</sup>Department of Paediatrics, University of Melbourne, Melbourne, Australia; <sup>c</sup>Heart Research Group, Murdoch Children's Research Institute, Melbourne, Australia; and <sup>d</sup>Melbourne Children's Centre for Cardiovascular Genomics and Regenerative Medicine, Melbourne, Australia.

Received for publication May 12, 2020; revisions received June 1, 2020; accepted for publication June 4, 2020; available ahead of print Aug 3, 2020.

Address for reprints: Igor E. Konstantinov, MD, PhD, FRACS, Royal Children's Hospital, Flemington Rd, Parkville 3029, Australia (E-mail: [igor.konstantinov@rch.org.au](mailto:igor.konstantinov@rch.org.au)).

J Thorac Cardiovasc Surg 2021;161:244-50  
0022-5223/\$36.00

Crown Copyright © 2020 Published by Elsevier Inc. on behalf of The American Association for Thoracic Surgery

<https://doi.org/10.1016/j.jtcvs.2020.06.145>

### CENTRAL MESSAGE

Aortic valve repair in infants is the best option, whereas it gives similar outcomes to the Ross operation in older children.

### ROSS PROCEDURE

The Ross operation can be performed in neonates and infants, although with inferior results compared with the outcomes in older children and adults.<sup>6,7</sup> Ivanov and colleagues<sup>8</sup> reported 79 children who underwent the Ross operation with an early mortality of 1.3%, with the only death in a neonate. Freedom from reintervention was 90% at 10 years after the Ross operation. They conclude that wider use of the Ross procedure in younger patients is warranted.

Riggs and colleagues<sup>9</sup> report 40 patients who underwent a supported Ross procedure between 2005 and 2018 at a median age of 16 years (range, 10-35 years). Their technique of supported Ross operation involves implantation of the autograft within a prosthetic graft. There were no early or late deaths. There had been 1 aortic valve replacement at a median follow-up of 3.5 years. Freedom from aortic root dilatation was 80% at 10 years. They concluded that a supported Ross procedure has excellent midterm results with minimal neo-aortic root dilatation.

Donald and colleagues<sup>10</sup> reported 140 children who underwent Ross procedure between 1995 and 2018. Operative mortality was 17% in neonates and infants and 0% in children aged more than 1 year. Survival at 10 years was 79% in neonates and infants compared with 96% in older children. Freedom from reoperation at 10 years was 62% for infants and 90% for older children. Donald and colleagues<sup>10</sup>

**Aortic valve surgery in children**

		Neonates and infants	Older children
Autologous tissue	Aortic valve repair	<ul style="list-style-type: none"> <li>• Early mortality: 3–4%</li> <li>• 10-year survival: 94%</li> <li>• 10-year freedom from reoperation: 66%</li> </ul>	<ul style="list-style-type: none"> <li>• Early mortality: 0.4–1.8%</li> <li>• 10-year survival: 94%</li> <li>• 10-year freedom from reoperation: 70%</li> </ul>
	Ross operation	<ul style="list-style-type: none"> <li>• Early mortality: 10–17%</li> <li>• 10-year survival: 79%</li> <li>• 10-year freedom from reoperation: 62%</li> </ul>	<ul style="list-style-type: none"> <li>• Early mortality: 0–4%</li> <li>• 10-year survival: 96%</li> <li>• 10-year freedom from reoperation: 90%</li> </ul>
	Ozaki aortic valve replacement	<ul style="list-style-type: none"> <li>• Not reported</li> </ul>	<ul style="list-style-type: none"> <li>• Early mortality: 0%</li> <li>• 10-year survival: not reported</li> <li>• 3-year freedom from reoperation: 80%</li> </ul>
Non-autologous material	Mechanical aortic valve replacement	<ul style="list-style-type: none"> <li>• Not feasible</li> </ul>	<ul style="list-style-type: none"> <li>• Early mortality: 0.5–7%</li> <li>• 10-year survival: 82%</li> <li>• 10-year freedom from reoperation: 78%</li> </ul>
	Homograft aortic valve replacement	<ul style="list-style-type: none"> <li>• Not reported</li> </ul>	<ul style="list-style-type: none"> <li>• Early mortality: 5–13%</li> <li>• 10-year survival: 85%</li> <li>• 10-year freedom from valve reoperation: 50–60%</li> </ul>

**FIGURE 1.** Comparative outcomes of aortic valve surgery in children using autologous tissues and nonautologous material. Reoperation rate in Ross operation refers to autograft reoperation.

showed that the Ross procedure should be delayed beyond infancy when possible to achieve the best results. Although the data on the Ross operation in children with infective endocarditis are limited, from the data available it appears that the Ross operation is an excellent option in children with endocarditis.<sup>11-13</sup>

**OZAKI AORTIC VALVE REPLACEMENT**

Aortic valve replacement in children using the Ozaki technique has been reported recently.<sup>14,15</sup> Originally, Ozaki and colleagues<sup>16</sup> reported 850 patients who underwent aortic valve neocuspidization between 2007 and 2015 in a predominantly adult population ranging from 13 to 90 years of age. Survival and freedom from reoperation at 10 years were 86% and 95%, respectively. Cumulative incidence of moderate or greater aortic regurgitation was 7.3% at 10 years. These initial midterm results demonstrated acceptable performance of the Ozaki techniques across a broad range of ages.

This year, Baird and colleagues<sup>14</sup> reported 57 patients who underwent aortic valve neocuspidization between 2015 and 2019 at a median age of 12.4 years. It should be noted that all but 1 of their 57 patients were aged more than 1 year and 9 patients were aged more than 18 years.

There were no operative mortalities. Freedom from reoperation was 91% at 1.5 years follow-up. They concluded that the Ozaki technique provides acceptable short-term results.

Wiggins and colleagues<sup>15</sup> reported 58 patients who underwent aortic valve tricuspidization by the Ozaki technique (n = 40) or a single-cusp reconstruction using the Ozaki principle (n = 18) between 2015 and 2019 at a median age of 15 years. Freedom from reoperation at 3 years was 80%. There were no early deaths. By 28 months, 10.3% of patients (6/58) had reoperations: Ross operation (n = 1), aortic valve replacement with mechanical valve (n = 2), and aortic root replacement with homograft (n = 1). Current techniques use nonviable tissue making the Ozaki technique comparable to an aortic valve replacement. If this technique could be modified using bioengineered tissue with regeneration and growth potential, it may become valuable in the future.<sup>17</sup>

**MECHANICAL AORTIC VALVE REPLACEMENT**

Myers and colleagues<sup>18</sup> reported 121 children who underwent mechanical aortic valve replacement between 2000 and 2014 at a median age of 16 years. They demonstrated an early mortality of 5.5% and a 10-year survival

of 82%. Freedom from reoperation was 78% at 10 years. Pannus ingrowth and valve thrombosis were the most common reasons for reoperation. They found younger age and use of a 16-mm prosthesis were risk factors for reoperation. In the recent meta-analysis by Etnel and colleagues,<sup>19</sup> the early mortality was 7%, late mortality was 1.2% per year, and reoperation rate was 1% per year after mechanical valve replacement in children.

### HOMOGRAFT AORTIC VALVE REPLACEMENT

Fukushima and colleagues<sup>20</sup> reported 840 patients who underwent homograft aortic valve replacement between 1973 and 2008, of whom 61 (7.3%) were children. Survival in children was 85% at 10 years, and freedom from structural valve deterioration was only 55% at 10 years. Younger age was independently associated with a higher risk of structural valve deterioration.

Sharabiani and colleagues<sup>21</sup> described 53 patients with a median age of 16 years operated between 2000 and 2012 and reported an early mortality of 2.1% and freedom from reoperation of 60% at 12 years of follow-up.

The use of homografts in neonates and infants is limited to case report and small series.<sup>18,22</sup> The largest series described 15 neonates and infants, with an operative mortality of 40% (6/15), and no long-term outcomes were reported.<sup>22</sup>

### COMPARATIVE STUDIES

Overall, it appears from the current literature that aortic valve repair provides the best outcomes in neonates and infants, whereas both aortic valve repair and Ross operation give best results for older children (Figure 1). Etnel and colleagues<sup>19</sup> reported a meta-analysis of 42 studies conducted between 1991 and 2015, comparing the results of the Ross procedure, homograft aortic valve replacement, and mechanical aortic valve replacement in children. They demonstrated lower early and late mortality with the Ross procedure compared with homograft and mechanical replacement. However, in infants, the Ross procedure was associated with 17% early mortality. The Ross procedure (1.6%/year) and mechanical aortic valve replacement (1.1%/year) had similar rates of aortic valve reoperation, whereas homografts had a significantly higher rate of reoperation (5.4%/year).

A clear-cut survival advantage of Ross operation compared with mechanical valve replacement has been demonstrated in adults.<sup>7</sup> One would expect similar results in children, in whom mechanical valve replacement is more challenging. Sharabiani and colleagues<sup>21</sup> reported 629 aortic valve operations performed in children between 2000 and 2012 from a national database. In infants, they found early mortality for the Ross procedure of 10%, and freedom from aortic valve reoperation of 85% at 10 years. In older children, 77.2% underwent the Ross procedure,

whereas 17.3% underwent mechanical aortic valve replacement. They found a significantly better event-free survival at 10 years in the patients who underwent the Ross procedure compared with patients who underwent mechanical valve replacement.

In the recent database study of 3446 children who underwent aortic valve replacement, Nelson and colleagues<sup>23</sup> demonstrated that children who underwent aortic valve replacement with a homograft had the highest early mortality. No late mortality or reoperation rate was reported in this large database study. Although homografts seem to have inferior performance compared with other modes of valve replacement, it is difficult to draw precise conclusions because children requiring homograft might have been sicker before surgery.

### CONCLUSIONS

Neonates and infants with congenital aortic stenosis have similar survival but improved freedom from reintervention when treated with aortic valve repair compared with balloon aortic dilatation. In neonates and infants, the Ross operation is associated with high operative mortality. In older children, the Ross operation has low early mortality and excellent freedom from reoperation. Ozaki aortic valve replacement could be performed without operative mortality, but the longer-term results are unknown. Aortic valve replacement with a mechanical prosthesis or a homograft has worse outcomes compared with the Ross operation.

### Conflict of Interest Statement

The authors reported no conflicts of interest.

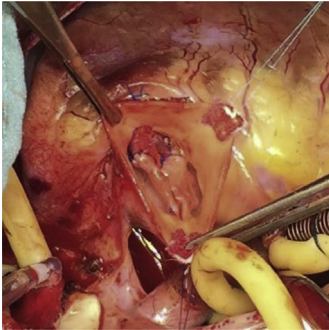
The *Journal* policy requires editors and reviewers to disclose conflicts of interest and to decline handling or reviewing manuscripts for which they may have a conflict of interest. The editors and reviewers of this article have no conflicts of interest.

### References

1. Bouhout I, Ba PS, El-Hamamsy I, Poirier N. Aortic valve interventions in pediatric patients. *Semin Thorac Cardiovasc Surg*. 2019;31:277-87.
2. Vergnat M, Asfour B, Arenz C, Suchowerskyj P, Bierbach B, Schindler E, et al. Aortic stenosis of the neonate: a single-center experience. *J Thorac Cardiovasc Surg*. 2019;157:318-26.
3. Siddiqui J, Brizard CP, Galati JC, Iyengar AJ, Hutchinson D, Konstantinov IE, et al. Surgical valvotomy and repair for neonatal and infant congenital aortic stenosis achieves better results than interventional catheterization. *J Am Coll Cardiol*. 2013;62:2134-40.
4. Konstantinov IE, Naimo PS, Buratto E. Commentary: Ozaki valve reconstruction in children: is it still a valve replacement? *J Thorac Cardiovasc Surg*. 2020 [Epub ahead of print].
5. d'Udekem Y, Siddiqui J, Seaman CS, Konstantinov IE, Galati JC, Cheung MM, et al. Long-term results of a strategy of aortic valve repair in the pediatric population. *J Thorac Cardiovasc Surg*. 2013;145:461-7.
6. Burkhart HM, Thompson JL, Anderson HN. Commentary: congenital aortic valve stenosis: defining the path to success. *Semin Thorac Cardiovasc Surg*. 2020 [Epub ahead of print].
7. Buratto E, Shi WY, Wynne R, Poh CL, Larobina M, O'Keefe M, et al. Improved survival after the Ross procedure compared with mechanical aortic valve replacement. *J Am Coll Cardiol*. 2018;71:1337-44.

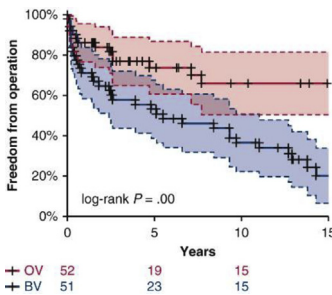
8. Ivanov Y, Drury NE, Stickley J, Botha P, Khan NE, Jones TJ, et al. Strategies to minimise need for prosthetic aortic valve replacement in congenital aortic stenosis-value of the Ross procedure. *Semin Thorac Cardiovasc Surg.* 2020 [Epub ahead of print].
9. Riggs KW, Colohan DB, Beacher DR, Alsaied T, Powell S, Moore RA, et al. Mid-term outcomes of the supported Ross procedure in children, teenagers, and young adults. *Semin Thorac Cardiovasc Surg.* 2019 [Epub ahead of print].
10. Donald JS, Wallace FRO, Naimo PS, Fricke TA, Brink J, Brizard CP, et al. Ross operation in children: 23-year experience from a single institution. *Ann Thorac Surg.* 2020;109:1251-9.
11. Khoo B, Buratto E, Fricke TA, Gelbart B, Brizard CP, Brink J, et al. Outcomes of surgery for infective endocarditis in children: a 30-year experience. *J Thorac Cardiovasc Surg.* 2019;158:1399-409.
12. Ratschiller T, Sames-Dolzer E, Paulus P, Schimetta W, Muller H, Zierer AF, et al. Long-term evaluation of the Ross procedure in acute infective endocarditis. *Semin Thorac Cardiovasc Surg.* 2017;29:494-501.
13. Amir G, Frenkel G, Rotstein A, Nachum E, Bruckheimer E, Lowenthal A, et al. Urgent surgical treatment of aortic endocarditis in infants and children. *Pediatr Cardiol.* 2019;40:580-4.
14. Baird CW, Sefton B, Chavez M, Sleeper LA, Marx GR, del Nido PJ. Congenital aortic and truncal valve reconstruction utilizing the Ozaki technique: short-term clinical results. *J Thorac Cardiovasc Surg.* February 18, 2020 [Epub ahead of print].
15. Wiggins LM, Mimic B, Issitt R, Ilic S, Bonello B, Marek J, et al. The utility of aortic valve leaflet reconstruction techniques in children and young adults. *J Thorac Cardiovasc Surg.* 2020;159:2369-78.
16. Ozaki S, Kawase I, Yamashita H, Uchida S, Takatoh M, Kiyohara N. Midterm outcomes after aortic valve neocuspidization with glutaraldehyde-treated autologous pericardium. *J Thorac Cardiovasc Surg.* 2018;155:2379-87.
17. Konstantinov IE, Fricke TA, Ivanov Y, Porrello E. Commentary: from bio-prosthetic tissue degeneration to regeneration: a new surgical horizon in the era of regenerative medicine. *J Thorac Cardiovasc Surg.* 2019;158:742-3.
18. Myers PO, Mokashi SA, Horgan E, Borisuk M, Mayer JE Jr, Del Nido PJ, et al. Outcomes after mechanical aortic valve replacement in children and young adults with congenital heart disease. *J Thorac Cardiovasc Surg.* 2019;157:329-40.
19. Etnel JR, Elmont LC, Ertekin E, Mikhles MM, Heuvelman HJ, Roos-Hesselink JW, et al. Outcome after aortic valve replacement in children: a systematic review and meta-analysis. *J Thorac Cardiovasc Surg.* 2016;151:143-52.
20. Fukushima S, Tesar PJ, Pearse B, Jalali H, Sparks L, Fraser JF, et al. Long-term clinical outcomes after aortic valve replacement using cryopreserved aortic allograft. *J Thorac Cardiovasc Surg.* 2014;148:65-72.
21. Sharabiani MT, Dorobantu DM, Mahani AS, Turner M, Peter Tometzki AJ, Angelini GD, et al. Aortic valve replacement and the ross operation in children and young adults. *J Am Coll Cardiol.* 2016;67:2858-70.
22. Woods RK, Pasquali SK, Jacobs ML, Austin EH, Jacobs JP, Krolikowski M, et al. Aortic valve replacement in neonates and infants: an analysis of the Society of Thoracic Surgeons Congenital heart surgery database. *J Thorac Cardiovasc Surg.* 2012;144:1084-9.
23. Nelson JS, Maul TM, Wearden PD, Pasquali SK, Romano JC. National practice patterns and early outcomes of aortic valve replacement in children and teens. *Ann Thorac Surg.* 2019;108:544-51.

**Key Words:** aortic valve repair, Ross procedure, homograft, Ozaki procedure, congenital aortic stenosis, children



**STCVS:** Aortic valve interventions in pediatric patients. Bouhout I, Ba PS, El-Hamamsy I, Poirier N. *Semin Thorac Cardiovasc Surg.* 2019; 31(2): 277-287.

**Commentary:** Aortic valve interventions in children: Still only scratching the surface. Myers PO, Pretre R. *Semin Thorac Cardiovasc Surg.* 2019; 31(2): 277-287.



**JTCVS:** Aortic stenosis of the neonate: A single-center experience. Vergnat M, Asfour B, Arenz C, Suchowerskyj P, Bierbach B, Schindler E, Schneider M, Hraska V. *J Thorac Cardiovasc Surg.* 2019; 157(1): 318-326.e1.

**Commentary:** A one-way street no more? Bacha E. *J Thorac Cardiovasc Surg.* 2019; 157(1): 327-328.

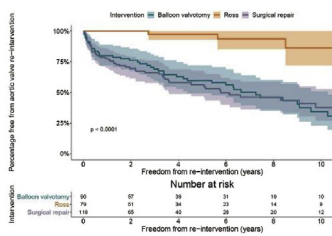


**JTCVS:** Congenital aortic and truncal valve reconstruction utilizing the Ozaki technique: Short-term clinical results. Baird C, Sefton B, Chavez M, Sleeper LA, Marx GR, del Nido PJ. *J Thorac Cardiovasc Surg.* 2020 [In press].

**Commentary:** A pediatric perspective on the Ozaki procedure. Karamlou T, Pettersson G, Nigro JJ. *J Thorac Cardiovasc Surg.* 2020 [In press].

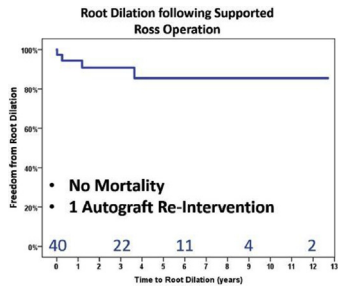
**Commentary:** Ozaki valve reconstruction in children: Is it still a valve replacement? Konstantinov IE, Naimo PS, Buratto E. *J Thorac Cardiovasc Surg.* 2020 [In press].

**Commentary:** Aortic valve reconstruction (AVRec) with neo-cuspidization: A word of caution? Bacha E. *J Thorac Cardiovasc Surg.* 2020 [In press].



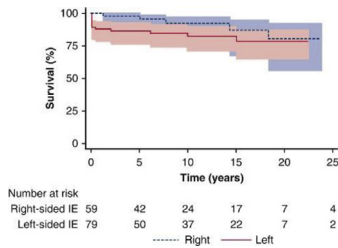
**STCVS:** Strategies to minimise need for prosthetic aortic valve replacement in congenital aortic stenosis—Value of the Ross Procedure. Ivanov Y, Drury NE, Stickley J, Botha P, Khan NE, Jones TJ, Brawn W, Barron DJ. *Semin Thorac Cardiovasc Surg.* 2020 [In press].

**Commentary:** Congenital aortic valve stenosis: Defining the path to success. Burkhart HM, Thompson JL, Anderson HN. *Semin Thorac Cardiovasc Surg.* 2020 [In press].



**STCVS:** Mid-term outcomes of the supported Ross Procedure in children, teenagers, and young adults. Riggs KW, Colohan DB, Beacher DR, Alsaied T, Powell, Moore RA, Ginde S, Tweddell JS. *Semin Thorac Cardiovasc Surg.* 2020 [In press].

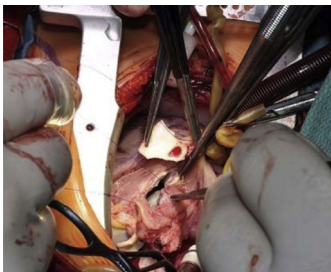
**Commentary:** “Growing” understanding of the autograft root. Kumar SR. *Semin Thorac Cardiovasc Surg.* 2020 [In press].



**JTCVS:** Outcomes of surgery for infective endocarditis in children: A 30-year experience. Khoo B, Buratto, E, Fricke TA, Gelbart B, Brizard CP, Brink J, d’Udekem Y, Konstantinov IE. *J Thorac Cardiovasc Surg.* 2019; 158(5): 1399-1409.

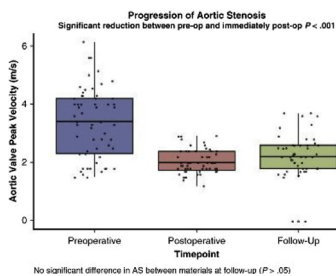
**Commentary:** Surgical outcome for infective endocarditis in children during long term follow-up. Takeuchi K. *J Thorac Cardiovasc Surg.* 2019; 159(5): 1411-1412.

**Commentary:** Purulence in the heart of a child? This should not be. *J Thorac Cardiovasc Surg.* Woods RK. *J Thorac Cardiovasc Surg.* 2019; 158(5): 1410.



**STCVS:** Long-term evaluation of the Ross Procedure in acute infective endocarditis. Ratschiller T, Sames-Dolzer E, Paulus P, Schimetta W, Muller H, Zierer AF, Mair R. *Semin Thorac Cardiovasc Surg.* 2017; 29(4): 494-501.

**Commentary:** Do the best until we know better... Yerebakan C. *Semin Thorac Cardiovasc Surg.* 2017; 29(4): 502-503.

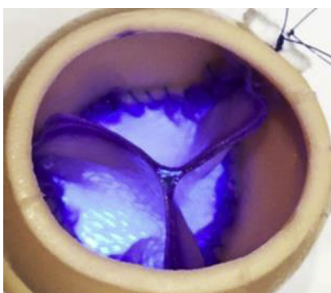

**JTCVS:** The utility of aortic valve leaflet reconstruction techniques in children and young adults. Wiggins LM, Mimic B, Issitt R, Ilic S, Bonello B, Marek J, Kostolny M. *J Thorac Cardiovasc Surg.* 2020; 159(6): 2369-2378.

**Commentary:** Are pediatric aortic leaflet reconstructions a long run for a short slide or a home run? Eckhauser A. *J Thorac Cardiovasc Surg.* 2020; 159(6): 2379.

**Commentary:** Aortic valve reconstruction and the Ozaki procedure in children—Finding the best fit. Shashidharan S, Chai P. *J Thorac Cardiovasc Surg.* 2020; 159(6): 2380.

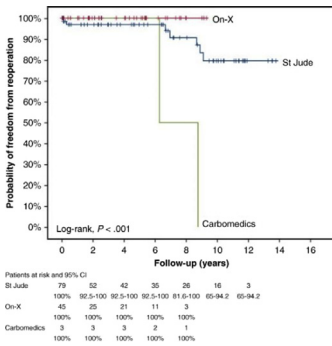
**Commentary:** Continue to imitate the nature: We are getting closer. Yerebakan C. *J Thorac Cardiovasc Surg.* 2020; 159(6): 2381-2382.



**JTCVS:** Midterm outcomes after aortic valve neocuspidization with glutaraldehyde-treated autologous pericardium. Ozaki S, Kawase I, Yamashita H, Uchida S, Takatoh M, Kiyohara N. *J Thorac Cardiovasc Surg.* 2018; 155(6): 2379-2387.

**Commentary:** Aortic valve: To buy or not to buy? Kim J, Lee JW. *J Thorac Cardiovasc Surg.* 2018; 155(6): 2388-2389.

**Commentary:** What goes around comes around...Possibly! Feindel C, Naimark A. *J Thorac Cardiovasc Surg.* 2019; 155(6): 2377-2378.



**JTCVS:** Outcomes after mechanical aortic valve replacement in children and young adults with congenital heart disease. Myers PO, Mokashi SA, Horgan E, Borisuk M, Mayer JE, del Nido PJ, Baird CW. *J Thorac Cardiovasc Surg.* 2019; 157(1): 329-340.

**Commentary:** Shedding more light on the use of mechanical aortic valve replacement in patients with congenital heart disease. Chai PJ. *J Thorac Cardiovasc Surg.* 2019; 157(1): 341.