

## Circulatory benefits of diastolic counterpulsation in an ischemic heart failure model after aortomyoplasty

Nasim Hedayati, MD<sup>a</sup>  
J. Timothy Sherwood, MD<sup>a</sup>  
Steve J. Schomisch, BS<sup>a</sup>  
Joseph L. Carino, BS<sup>b</sup>  
Brian L. Cmolik, MD<sup>a,b</sup>

From the University Hospitals of Cleveland,<sup>a</sup> Case Western Reserve University School of Medicine, and the Cleveland Veterans Affairs Medical Center,<sup>b</sup> Cleveland, Ohio.

Supported by: Office of Research and Development, Medical Research Service, Department of Veterans Affairs and American Heart Association, Ohio Valley Affiliate. Dr Hedayati is an Allen Fellow supported by the Jay L. Ankeney Endowed Professorship in Cardiothoracic Surgery, Case Western Reserve University School of Medicine, Cleveland, Ohio.

Read at the Eighty-first Annual Meeting of The American Association for Thoracic Surgery, San Diego, Calif, May 6-9, 2001.

Received for publication May 15, 2001; revisions requested Sept 12, 2001; revisions received Oct 8, 2001; accepted for publication Nov 7, 2001.

Address for reprints: Brian L. Cmolik, MD, University Hospitals of Cleveland, Cardiothoracic Surgery, 11100 Euclid Ave, Cleveland, OH 44106-5011 (E-mail: blc3@po.cwru.edu).

J Thorac Cardiovasc Surg 2002;123:1067-73

12/6/121682

doi:10.1067/mtc.2002.121682

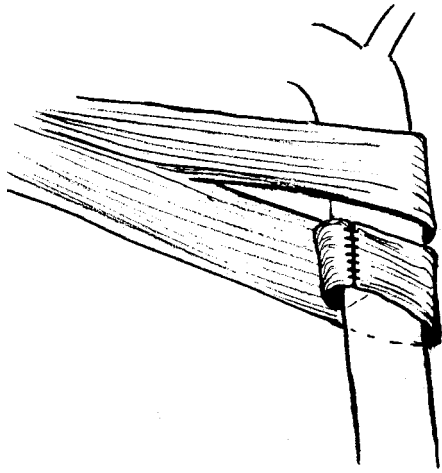
**Objective:** Aortomyoplasty is an experimental surgical procedure in which the latissimus dorsi muscle is wrapped around the thoracic aorta and stimulated to contract during diastole, providing diastolic counterpulsation. We hypothesized that aortomyoplasty could improve cardiac function in a chronic ischemic heart failure model, similar to the improvement seen with the intra-aortic balloon pump.

**Methods:** Six dogs (25-30 kg) successfully underwent aortomyoplasty followed by serial coronary microembolization. Ejection fraction decreased from 63.5% to 36.5%. Two weeks after the final microembolization, the muscle was conditioned for 4 months to achieve fatigue resistance. One year after aortomyoplasty, hemodynamic studies during 1 hour of aortomyoplasty and 1 hour of intra-aortic balloon counterpulsation determined mean diastolic aortic pressure, peak left ventricular pressure, and endocardial viability ratio for assisted and unassisted beats. Cardiac output, stroke volume, and parameters of cardiac function were also measured.

**Results:** Endocardial viability ratio increased by  $23.8\% \pm 7.9\%$  ( $P = .001$ ) with aortomyoplasty counterpulsation and by  $22.7\% \pm 12.9\%$  ( $P = .021$ ) with the intra-aortic balloon pump. Both aortomyoplasty and the intra-aortic balloon pump significantly increased mean diastolic aortic pressure and reduced peak left ventricular pressure. Improvements in cardiac function with aortomyoplasty and the intra-aortic balloon pump were similar. Cardiac output increased from  $2.61 \pm 0.88$  to  $3.07 \pm 1.06$  L/min ( $P = .006$ ), and index of afterload decreased from  $5.4 \pm 1.4$  to  $4.8 \pm 1.4$  mm Hg/mL ( $P = .02$ ) during 1 hour of aortomyoplasty counterpulsation.

**Conclusion:** One year after the procedure, aortomyoplasty counterpulsation provided diastolic augmentation and improved cardiac performance similar to the improvement provided by the intra-aortic balloon pump in a chronic ischemic heart failure model. Aortomyoplasty has the potential to benefit patients with ischemic heart disease refractory to current therapies.

Ischemic heart disease affects 26,000,000 Americans.<sup>1</sup> Angioplasty and coronary artery bypass grafting have been the mainstay therapies, with 1.48 million procedures performed in 1998.<sup>1</sup> Each year approximately 100,000 patients who are not candidates for revascularization continue to experience ischemic symptoms despite maximal medical therapy.<sup>2</sup> As a result, there has been a growing interest in alternative therapies and assist devices for patients with ischemic heart failure who cannot be helped by pharmacologic treatment, are not candidates for revascularization, or are awaiting a heart transplant.



**Figure 1. Aortomyoplasty wringer wrap configuration: LDM wrapped around descending thoracic aorta.**

Ischemia caused by compromised perfusion leads to myocardial hibernation, a state of left ventricular contractile dysfunction that is often reversed by revascularization and an improvement in myocardial oxygen supply.<sup>3,4</sup> Diastolic counterpulsation can improve myocardial oxygen supply by increasing coronary perfusion and can decrease myocardial oxygen demand by reducing afterload. The most common form of diastolic counterpulsation is the intra-aortic balloon pump (IABP). The IABP continues to be beneficial for complications of myocardial infarction, end-stage cardiomyopathy, and postcardiotomy cardiogenic shock.<sup>5-7</sup> Refractory unstable angina has also been treated with the IABP<sup>5-7</sup> and the enhanced external counterpulsation device, which uses external compression of the lower extremities to augment diastole.<sup>8</sup>

An experimental surgical procedure that generates autologous diastolic counterpulsation is aortomyoplasty, in which the latissimus dorsi muscle (LDM) is wrapped around the ascending or descending thoracic aorta and stimulated to contract during diastole. Aortomyoplasty can increase coronary blood flow through diastolic augmentation<sup>9-11</sup> and can decrease left ventricular work through afterload reduction.<sup>12</sup> Although the application of skeletal muscle extra-aortic counterpulsation is not a new idea and has had limited success clinically, indications for its use have been diverse.<sup>13,14</sup> We propose that the enhanced coronary perfusion of chronic aortomyoplasty counterpulsation may benefit patients with ischemic heart disease who have exhausted pharmacologic options and are not candidates for revascularization.

Previous work in our laboratory involved optimizing aortomyoplasty muscle stimulation to cardiac cycle timing, showing an increase in coronary blood flow with aortomyoplasty counterpulsation, optimizing muscle wrap configura-

tion to yield the greatest hemodynamic benefits, and demonstrating the integrity of the LDM 6 months after aortomyoplasty.<sup>9,15-17</sup> The purpose of this investigation was to confirm the long-term stability of the aortomyoplasty muscle wrap and to evaluate the efficacy of acute aortomyoplasty counterpulsation in comparison with the IABP in a chronic ischemic heart failure model. We hypothesized that 1 year after the procedure, aortomyoplasty counterpulsation would provide cardiac benefits equivalent to the IABP in a chronically ischemic heart.

### Material and Methods

Six male mongrel dogs (25-30 kg) completed the study. The procedures were performed in compliance with the "Principles of Laboratory Animal Care" of the National Society for Medical Research and the "Guide for the Care and Use of Laboratory Animals" prepared by the Institute of Laboratory Animal Resources, National Research Council, and published by the National Academy Press, revised 1996. The Case Western Reserve University Institutional Animal Care and Usage Committee also approved the protocol.

### Descending Aortomyoplasty

Ten mongrel dogs underwent aortomyoplasty. General anesthesia was induced with buprenorphine (0.3 mg subcutaneously) and sodium thiopental (25 mg/kg intravenously). After endotracheal intubation, anesthesia was maintained with isoflurane (1%-2%). Prophylactic cefazolin (1 g) and fluids were administered intravenously. The animal was monitored by continuous electrocardiography (ECG) and pulse oximetry. In the left thoracotomy position, an axillary incision extending to midthorax was made for the left LDM to be mobilized. The neurovascular bundle was preserved, and intramuscular pacing electrodes were implanted near the thoracodorsal nerve. The electrodes were tunneled subcutaneously to exit between the scapulae, where they were later attached to a portable stimulator. Through a left fifth interspace thoracotomy, the descending thoracic aorta was exposed, and several intercostal arteries were ligated as needed to allow the muscle to be wrapped around the aorta. After resection of a 4-cm portion of the second rib, the LDM was transposed into the chest. With the "wringer wrap" configuration developed in our laboratory (Figure 1), the LDM was divided longitudinally, with the oblique-transverse portion wrapped clockwise around the proximal part of the descending thoracic aorta and the lateral portion of the muscle wrapped counterclockwise distally.<sup>15</sup> The muscle was then secured to itself.

### Microembolization

Several months after aortomyoplasty, serial coronary microembolizations were performed. General anesthesia was induced with diazepam (0.165 mg/kg intravenously), pentobarbital (10 mg/kg intravenously), and hydromorphone (0.29 mg/kg intravenously). After endotracheal intubation, prophylactic cefazolin (1 g) and fluids were administered intravenously. Animals were monitored throughout the procedure with a continuous ECG and pulse oximetry. After isolation of the femoral artery to catheterize the left heart, heparin (1500 units intravenously) was administered. A Judkins preformed coronary catheter (JL-4) was positioned in the left anterior descending or circumflex coronary artery under fluo-

roscopic guidance. Subsequently, a mixture consisting of 0.5-mL Polybead (Polysciences Inc, Warrington, Pa) polystyrene microspheres (90  $\mu\text{m}$  in diameter, approximately 40,000 particles/[mL  $\cdot$  injection]) with 0.5-mL radiographic contrast suspension (iothalamate meglumine; Mallinckrodt Inc, St Louis, Mo) was delivered by bolus injection into the artery.

During each session, an average of three injections were delivered at 15-minute intervals. The ECG was monitored for ischemic changes and arrhythmias. After embolization, propranolol (1 mg) to minimize catecholamine surge and protamine (15 mg) to reverse heparin were administered intravenously. The femoral artery was then primarily repaired, and the incision was closed. Each animal underwent approximately 9 to 14 weekly sessions of microembolization. The left ventricular ejection fraction was measured with contrast ventriculography digital analysis (Simpson method). Once ejection fraction had decreased to approximately 35% (from baseline of  $63.5\% \pm 6.0\%$  to  $36.5\% \pm 3.6\%$ ,  $P < .05$ ), the microembolization sessions were discontinued. Six dogs survived the microembolization procedures.

### Muscle Conditioning

Two weeks after the final microembolization, long-term muscle conditioning was initiated and was continued for approximately 4 months. A fitted jacket securing a portable stimulator was attached to the muscle pacing electrodes that exited between the scapulae. The stimulator was programmed to supply a pulse frequency of 2 Hz (24 h/d) with an amplitude of 3 to 4 V and a pulse width of 210  $\mu\text{s}$ , sufficient to twitch the LDM.<sup>18</sup> The twitch was detected by palpation of the left axillary region. The 2-Hz frequency protocol is well documented for developing a fatigue-resistant LDM by converting the type II (fast twitch) muscle fibers to type I (slow twitch) muscle fibers.<sup>19,20</sup>

### Hemodynamic Studies

Four months after the final microembolization session (1 year after aortomyoplasty), peak left ventricular pressure, mean diastolic aortic pressure, and endocardial viability ratio were measured for assisted and unassisted beats during 1 hour of aortomyoplasty and 1 hour of IABP counterpulsation. Endocardial viability ratio is the ratio of the diastolic pressure time index to systolic tension-time index, which correlates to the myocardial oxygen supply-to-demand ratio and is an index of the extent of counterpulsation.<sup>21</sup>

General anesthesia was induced as for the aortomyoplasty surgery. A 7.5F Swan-Ganz catheter (Baxter Healthcare Corp, Edwards Division, Santa Ana, Calif) was positioned to measure pressures, cardiac output (CO), and stroke volume. Under fluoroscopic guidance, a combination pressure and conductance catheter (Millar Instruments, Inc, Houston, Tex) was advanced through the carotid artery into the left ventricle. The conductance catheter was attached to a signal conditioner and processor for calculation of an uncalibrated volume signal (Leycom Sigma 5; Cardiodynamics, Zoetermeer, The Netherlands). Stroke volume and ejection fraction were used to calibrate the volume signal. Analog signals were continuously monitored (Gould Electronics Inc, Eastlake, Ohio) and were recorded digitally by computer during a respiratory pause.

The left ventricular pressure and volume data were used to plot pressure-volume loops during 1:2 aortomyoplasty and 1:2 IABP counterpulsation. For each sampling of the waveforms, the cardiac

cycles were separated into assisted and unassisted beats to compare the extent of augmentation. The following indices were derived from the pressure-volume loops: maximal elastance ( $E_{\text{max}}$ ), the slope of the end-systolic pressure and volume relationship or the index of contractility; effective arterial elastance ( $E_{\text{a}}$ ), the ratio of the end-systolic pressure to stroke volume or the index of afterload; preload recruitable stroke work (PRSW), the ratio of stroke work to end-diastolic volume; and the ventriculoarterial (VA) coupling index ( $E_{\text{a}}/E_{\text{max}}$ ), the relationship between the ventricular elastance and the arterial afterload. A VA coupling index value of 1 indicates optimal cardiac performance.

During 1 hour of aortomyoplasty counterpulsation, the LDM was stimulated by a bench-top stimulator (AstroMed, Inc, Grass Instrument Division, West Warwick, RI) connected to a customized computer program designed in our laboratory incorporating Labview (National Instruments Corporation, Austin, Tex). This software provided the timing and duration of the impulse relative to the ECG waveform. The LDM was stimulated with a pulse frequency of 30 Hz, amplitude of 4 to 10 V, and pulse width of 210  $\mu\text{s}$  duration during every other cardiac cycle, initiated at the dicrotic notch and terminated during isovolumic contraction.

Finally, each animal underwent 1 hour of IABP counterpulsation while hemodynamic measurements were recorded. A 9.5F IABP catheter (System 98 Pump; Datascope Corp, Montvale, NJ) with a 25-mL balloon was introduced through the femoral artery, and its position was confirmed under fluoroscopy. The IABP activation was set at a 1:2 ratio, and conventional timing was employed such that the balloon was inflated at the dicrotic notch and deflated to yield a presystolic dip (minimal aortic pressure).

### Statistical Analysis

Comparisons of the hemodynamic indices between the assisted and unassisted beats and the cardiac function indices during unassisted beats at the start and the end of 1 hour of counterpulsation were analyzed with paired *t* tests. All results are expressed as mean  $\pm$  SD.

## Results

### Outcomes and Adverse Events

Ten healthy male mongrel dogs successfully underwent aortomyoplasty without neurologic sequelae. Skin infection at the exit site of the muscle pacing electrodes was noted in 5 animals. The infections were treated with an antibiotic (cephalexin, 1 g orally twice daily) and local wound care. Procainamide (500 mg) was administered intravenously to treat arrhythmias associated with the microembolization procedure. Each animal received a diuretic (furosemide, 10-20 mg orally twice daily) as needed for evidence of pulmonary edema. Four dogs died of arrhythmia during the microembolization procedures, before long-term muscle conditioning. Six dogs successfully completed serial coronary microembolization, long-term muscle conditioning, and hemodynamic studies.

### Hemodynamic Effects

One hour of counterpulsation during every other cardiac cycle with aortomyoplasty and the IABP produced similar

**TABLE 1. Indices of hemodynamic augmentation: Aortomyoplasty counterpulsation versus the IABP in an ischemic heart failure model**

	Start				End			
	Nonaugmented	Augmented	<i>P</i> value	% Increase	Nonaugmented	Augmented	<i>P</i> value	% Increase
<b>Aortomyoplasty</b>								
Endocardial viability ratio	1.205 ± 0.410	1.487 ± 0.483	.001	23.8 ± 7.9	1.177 ± 0.285	1.404 ± 0.303	.001	19.9 ± 7.8
Mean diastolic aortic pressure (mm Hg)	98.5 ± 24.0	114.0 ± 27.3	.001	15.8 ± 3.9	96.4 ± 23.5	108.0 ± 26.0	.001	12.1 ± 207
Peak left ventricular pressure (mm Hg)	120.8 ± 27.4	118.0 ± 26.6	.001	-2.3 ± 0.3	120.0 ± 26.7	116.8 ± 25.4	.02	-2.6 ± 1.6
<b>IABP</b>								
Endocardial viability ratio	1.234 ± 0.162	1.526 ± 0.358	.021	22.7 ± 12.9	1.247 ± 0.181	1.525 ± 0.378	.021	21.0 ± 11.7
Mean diastolic aortic pressure (mm Hg)	89.2 ± 22.9	104.5 ± 26.9	.006	17.5 ± 9.5	89.1 ± 21.6	103.8 ± 25.0	.005	16.8 ± 8.9
Peak left ventricular pressure (mm Hg)	112.2 ± 25.5	109.7 ± 24.9	.009	-2.2 ± 1.3	112.2 ± 24.6	110.0 ± 24.1	.004	-2.0 ± 0.9

Values are mean ± SD. *Start* represents mean value of the first 10 minutes of augmentation; *End* represents mean value of the final 10 minutes of augmentation.

hemodynamic improvements. The myocardial oxygen supply-to-demand ratio, endocardial viability ratio, increased by 23.8% ± 7.9% ( $P = .001$ ) during assisted beats with aortomyoplasty and by 22.7% ± 12.9% ( $P = .021$ ) with the IABP (Table 1). Both aortomyoplasty and the IABP significantly increased mean diastolic aortic pressure and reduced peak left ventricular pressure. Furthermore, the mean value of the hemodynamic improvements at the start of the hour did not differ significantly from the values at the end of the hour.

### Effects on Cardiac Performance

To further evaluate the efficacy of counterpulsation, the average cardiac function indices for the unassisted beats during the first 10 minutes of augmentation were compared with the values during the final 10 minutes. Neither aortomyoplasty nor the IABP significantly changed the heart rate throughout the hour of counterpulsation (Table 2). Although  $E_{max}$ , an index of contractility, increased with both aortomyoplasty (2.9 ± 1.3 to 3.1 ± 1.4 mm Hg/mL) and the IABP (3.2 ± 1.6 to 3.4 ± 1.8 mm Hg/mL), the difference did not reach statistical significance. During aortomyoplasty counterpulsation,  $E_a$  decreased from 5.4 ± 1.4 to 4.8 ± 1.4 mm Hg/mL ( $P = .006$ ), indicating a reduced afterload. The IABP also decreased  $E_a$  (5.1 ± 2.0 to 4.8 ± 1.6 mm Hg/mL), but this decrease did not achieve statistical significance. PRSW increased with both methods, indicating an increase in stroke work throughout the hour, a decrease in end-diastolic volume throughout the hour, or both. Stroke volume increased with aortomyoplasty (24.3 ± 8.3 to 26.4 ± 7.6 mL) but not with the IABP (25.2 ± 8.3 to 25.6 ± 8.0 mL). This in turn was reflected in a statistically significant increase in CO during aortomyoplasty, from 2.61 ± 0.88 to 3.07 ± 1.06 L/min ( $P = .02$ ). The VA coupling

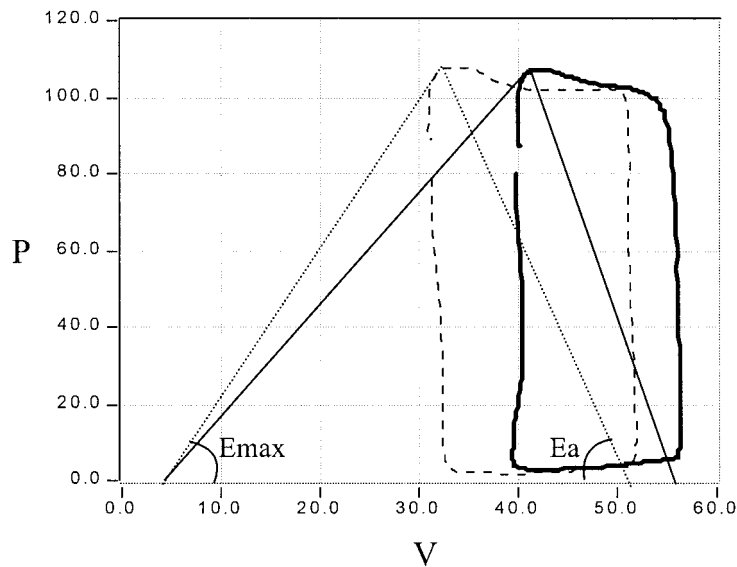
index ( $E_a/E_{max}$ ) decreased from 2.1 ± 0.7 to 1.8 ± 0.8 during aortomyoplasty and from 1.8 ± 0.9 to 1.7 ± 0.8 during IABP counterpulsation.

A pressure-volume analysis for the averaged unassisted beats, comparing the start with the end of 1 hour of aortomyoplasty counterpulsation for a single animal, is presented in Figure 2. The leftward shift of the pressure-volume loop from the start to the end of the hour represents improved cardiac performance, with an increase in  $E_{max}$  (contractility) and a decrease in  $E_a$  (afterload). Figure 3 represents the trends in the indices of cardiac function during aortomyoplasty counterpulsation. The values are percentage changes relative to the baseline. With the onset of counterpulsation, there were gradual increases in stroke volume, CO,  $E_{max}$ , and PRSW and a decrease in  $E_a$  as the hour progressed. When the LDM stimulation was turned off, all values approached baseline.

### Discussion

The IABP benefitted 155,000 patients globally in 1999 (Datascope Corp, personal communication). As the criterion standard of diastolic counterpulsation, the IABP has assisted patients with cardiogenic shock, unstable angina, and myocardial infarction; however, its long-term use remains limited by such complications as thromboembolic events and infection.<sup>5-7</sup> Aortomyoplasty is a surgical procedure that can provide autologous and hemocompatible counterpulsation. Because it is not limited by the complications of the IABP, its potential to benefit the ischemic heart on a long-term basis as an adjunct to current therapies needs to be explored.

Successful diastolic counterpulsation enhances coronary perfusion by diastolic augmentation and reduces left ven-



**Figure 2.** Pressure-volume analysis during aortomyoplasty counterpulsation. Averaged unassisted pressure-volume loop of single animal at start (solid line) and end (dashed line) of 1 hour of aortomyoplasty counterpulsation. *P*, Pressure in millimeters of mercury; *V*, volume in milliliters.

**TABLE 2.** Indices of cardiac performance: Aortomyoplasty counterpulsation versus the IABP in an ischemic heart failure model

	Aortomyoplasty			IABP		
	Start	End	<i>P</i> value	Start	End	<i>P</i> value
Heart rate (beats/min)	114.7 ± 22.7	117.5 ± 25.9	.429	111.3 ± 23.3	114.0 ± 22.4	.323
$E_{max}$ (mm Hg/mL)	2.9 ± 1.3	3.1 ± 1.4	.610	3.2 ± 1.6	3.4 ± 1.8	.393
$E_a$ (mm Hg/mL)	5.4 ± 1.4	4.8 ± 1.4	.006	5.1 ± 2.0	4.8 ± 1.6	.431
$E_a/E_{max}$	2.1 ± 0.7	1.8 ± 0.8	.262	1.8 ± 0.9	1.7 ± 0.8	.140
PRSW (mm Hg)	38.1 ± 15.9	41.6 ± 16.6	.357	39.7 ± 18.4	41.4 ± 18.8	.068
Stroke volume (mL)	24.3 ± 8.3	26.4 ± 7.6	.134	25.2 ± 8.3	25.6 ± 8.0	.751
CO (L/min)	2.61 ± 0.88	3.07 ± 1.06	.020	2.81 ± 0.74	2.86 ± 0.95	.813

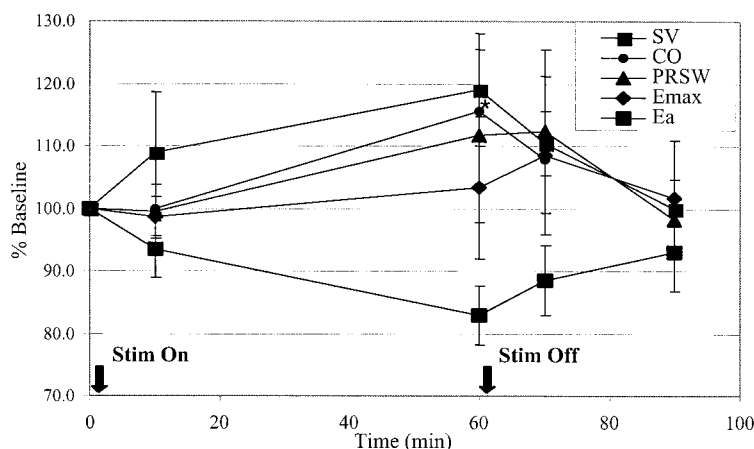
Values are mean of unassisted beats ± SD. *Start* represents mean value of the first 10 minutes of augmentation; *End* represents mean value of the final 10 minutes of augmentation.

tricular work by afterload reduction.<sup>22</sup> In this model of ischemic heart failure, we demonstrated improved cardiac function through sustained diastolic augmentation and afterload reduction during 1 hour of aortomyoplasty counterpulsation. Equally important was the observation that the hemodynamic augmentation during aortomyoplasty was comparable to that seen with the IABP.

Pressure-volume analysis of cardiac performance showed similar improvements after 1 hour of counterpulsation with aortomyoplasty and the IABP. Although the changes in such indices as  $E_{max}$ , PRSW, and CO did not reach statistical significance, there was an overall improvement in cardiac function during aortomyoplasty, as demonstrated in Figure 3. With the onset of counterpulsation,  $E_{max}$ , CO, and PRSW gradually increased, followed by a return to baseline after the LDM stimulation was turned off.

The overall decrease in the VA coupling index during 1 hour of counterpulsation supports the contention that both interventions were able to decrease afterload, increase ventricular contractility, or both. We speculate that the small number of animals in the study ( $n = 6$ ) and the moderate degree of ischemic damage could explain why certain values of cardiac performance did not reach statistical significance. Furthermore, a longer period of diastolic augmentation may be necessary for complete recovery of cardiac function.

Although heart failure models such as rapid ventricular pacing and propranolol administration have been used to demonstrate the effects of aortomyoplasty counterpulsation,<sup>12,19,21</sup> we chose the sequential coronary microembolization model for several reasons. Coronary microembolization leads to reduced ejection fraction, increased left



**Figure 3. One hour of aortomyoplasty counterpulsation in ischemic heart failure model. Values are percentage of baseline  $\pm$  SEM. Stim On, Start of counterpulsation; Stim Off, end of counterpulsation. Small squares, Stroke volume; circles, CO; triangles, PRSW; diamonds, E<sub>max</sub>; large squares, E<sub>a</sub>.**

ventricular end-diastolic pressure, and elevated plasma norepinephrine levels.<sup>23,24</sup> The chronic changes of this model support the argument that multiple embolizations will exhaust the compensatory mechanisms of the myocardium, leading to left ventricular dysfunction<sup>23</sup> and compromised coronary flow reserve.<sup>24</sup> A model of ischemic cardiac dysfunction can benefit the most from diastolic counterpulsation. This is the first study to our knowledge to examine aortomyoplasty in a chronic ischemic heart failure model.

Atherosclerotic plaque rupture and mural thrombus, followed by embolization in the coronary vessels, may be responsible for ischemic heart disease in human beings.<sup>3,25</sup> The compromised coronary flow in response to coronary microembolization leads to reduced myocardial contractile function and a new steady state of perfusion-contraction matching to preserve energy and prevent progressive ischemia.<sup>3,4</sup> It has been argued that downward regulation of energy requirement occurs with moderate myocardial ischemia.<sup>26</sup> This perfusion-contraction matching has been proposed to be a physiologic effect of the hibernating myocardium.<sup>3</sup> Myocardial function can be restored partially or completely if the supply and demand of oxygen is favorably changed by improving the blood supply,<sup>27,28</sup> as occurs with revascularization. Our results suggest that aortomyoplasty counterpulsation may also benefit a hibernating myocardium by enhancing myocardial oxygen supply and reducing myocardial demand.

The length of our study supports the long-term potential of aortomyoplasty. The LDM did not fatigue during the hour of counterpulsation, which confirms the adequate conditioning and the viability of the muscle 1 year after the operation. We have previously examined muscle viability 1 year after wringer wrap aortomyoplasty, demonstrating that biopsy samples of short-term-stimulated LDM revealed no evidence of necrosis, fibrosis, or fatty infiltration relative to

the contralateral LDM (unpublished data). Studies involving 12 to 24 months of long-term LDM stimulation after aortomyoplasty have also demonstrated no evidence of fibrosis, atrophy, or fatty infiltration of the wrapped muscle.<sup>29,30</sup>

Limitations of our study include the sole use of ejection fraction to quantify the extent of ischemic heart damage. Additional methods, such as the dobutamine stress test, might better evaluate the ischemic changes after serial coronary microembolization and subsequent improvement with counterpulsation. Furthermore, cardiac benefits of aortomyoplasty counterpulsation were evaluated mainly by pressure-volume analysis. Measurement of coronary blood flow and myocardial oxygen consumption could further demonstrate the benefits of counterpulsation.

In summary, aortomyoplasty can provide hemodynamic augmentation comparable to that of the IABP, but without the attendant complications.<sup>9,11,12</sup> We have demonstrated that acute aortomyoplasty counterpulsation improves cardiac function in a chronic ischemic heart failure model. Future studies should establish the ability of aortomyoplasty to provide long-term counterpulsation capable of attenuating the symptoms of ischemic heart disease. Evidence that long-term counterpulsation by means such as enhanced external counterpulsation devices can benefit patients with angina<sup>8</sup> supports the potential of long-term counterpulsation devices in the clinical setting. For patients with ischemic heart disease that is refractory to current therapies, aortomyoplasty may provide long-term relief through diastolic augmentation and systolic unloading.

## References

1. American Heart Association. 2000 Heart and Stroke Statistical Update. Dallas (TX): The Association; 1999.
2. Mukherjee D, Ellis SG. New options for untreatable coronary artery disease: angiogenesis and laser revascularization. *Cleve Clin J Med.* 2000;67:577-83.

3. Erbel R, Heusch G. Coronary microembolization. *J Am Coll Cardiol*. 2000;36:22-4.
4. Ross J Jr. Myocardial perfusion-contraction matching: implications for coronary heart disease and hibernation. *Circulation*. 1991;83:1076-83.
5. Quaal SJ. Indications. In: Quaal SJ. Comprehensive intraaortic balloon counterpulsation. 2nd ed. St Louis: Mosby-Year Book; 1997. p. 118-43.
6. Torchiana DF, Hirsch G, Buckley MJ, Hahn C, Allyn JW, Akins CW, et al. Intraaortic balloon pumping for cardiac support: trends in practice and outcome, 1968 to 1995. *J Thorac Cardiovasc Surg*. 1997; 113:758-64.
7. Eltchaninoff H, Dimas AP, Whitlow PL. Complications associated with percutaneous placement and use of intraaortic balloon counterpulsation. *Am J Cardiol*. 1993;71:328-32.
8. Lawson WE, Hui JCK, Cohn PF. Long-term prognosis of patients with angina treated with enhanced external counterpulsation: five-year follow-up study. *Clin Cardiol*. 2000;23:254-8.
9. Cmolik BL, Thompson DR, Sherwood JT, Geha AS, George DT. Increased coronary artery blood flow with aortomyoplasty in chronic heart failure. *Ann Thorac Surg*. 2001;71:284-9.
10. Bolotin G, Wolf T, van der Veen FH, Shofti R, Lorusso R, Shreuder JJ, et al. Acute descending aortomyoplasty induces coronary blood flow augmentation. *Ann Thorac Surg*. 1999;68:1668-75.
11. Bolotin G, Wolf T, Shachner R, van der Veen FH, Shofti R, Lorusso R, et al. Hemodynamic evaluation of descending aortomyoplasty versus intra-aortic balloon pump performed in normal animals: an acute study. *Eur J Cardiothorac Surg*. 2001;19:174-8.
12. Lazzara RR, Trumble DR, Magovern JA. Dynamic descending thoracic aortomyoplasty: comparison with intraaortic balloon pump in a model of heart failure. *Ann Thorac Surg*. 1994;58:366-71.
13. Chachques JC, Braunberger E, Lajos P, Argyriadis P, Shafy A, Latremouille C, et al. Biological counterpulsation with aortomyoplasty: experimental and clinical results. *Basic Appl Myol*. 1999;9:215-8.
14. Trainini J, Barisani J, Mouras J, Cabrera Fischer EI, Christen AI. Chronic aortic counterpulsation with latissimus dorsi: clinical follow-up. Cardiomyoplasty comparison. *Basic Appl Myol*. 2000;10:119-25.
15. Cmolik BL, Thompson DR, Sherwood JT, Rovner AL, Geha AS, George DT. Optimizing muscle wrap configuration for aortomyoplasty. *Basic Appl Myol*. 1999;9:167-73.
16. Thompson DR, Cmolik BL, Cheever EA, Geha AS, George DT. Optimizing muscle-to-cardiac timing for aortomyoplasty. *Biomed Sci Instrum*. 1997;33:486-90.
17. Sherwood JT, Thompson DR, Schomisch SJ, Stewart RW, George DT, Cmolik BL. Long-term diastolic counterpulsation with aortomyoplasty: hemodynamic effectiveness at 6 months. *Surg Forum*. 1999;L:176-8.
18. Cheever EA, Thompson DR, Cmolik BL, Santamore WP, George DT. A versatile microprocessor-based multichannel stimulator for muscle cardiac assist. *IEEE Trans Biomed Eng*. 1998;45:56-67.
19. Mannion JD, Bitto T, Hammond RL, Rubinstein NA, Stephenson LW. Histochemical and fatigue characteristics of conditioned canine latissimus dorsi muscle. *Circ Res*. 1986;58:298-304.
20. Ianuzzo CD, Hamilton N, O'Brien PJ, Desrosiers C, Chiu R. Biochemical transformation of canine skeletal muscle for use in cardiac-assist devices. *J Appl Physiol*. 1990;68:1481-5.
21. Cabrera Fischer EI, Christen AI, de Forteza E, Risk MR. Dynamic abdominal and thoracic aortomyoplasty in heart failure: assessment of counterpulsation. *Ann Thorac Surg*. 1999;67:1022-9.
22. Frazier OH. New technologies in the treatment of severe cardiac failure: the Texas Heart Institute experience. *Ann Thorac Surg*. 1995; 59(2 Suppl):S31-8.
23. Sabbah HN, Stein PD, Kono T, Gheorghiane M, Levine TB, Jafri S, et al. A canine model of chronic heart failure produced by multiple sequential coronary microembolizations. *Am J Physiol* 1991;260(4 Pt 2):H1379-84.
24. Blaustein AS, Hoit BD, Wexler LF, Ashraf M, Ramrakhyani K, Matoba R, et al. Characteristics of chronic left ventricular dysfunction induced by coronary embolization in a canine model. *Am J Cardiovasc Pathol*. 1994;5:32-48.
25. Erbel R, Heusch G. Coronary microembolization—its role in acute coronary syndromes and interventions. *Herz*. 1999;24:558-75.
26. Bristow JD, Arai AE, Anselone CG, Pantley GA. Response to myocardial ischemia as a regulated process. *Circulation*. 1991;84:2580-7.
27. Conversano A, Walsh JF, Geltman EM, Perez JE, Bergmann SR, Gropler RJ. Delineation of myocardial stunning and hibernation by positron emission tomography in advanced coronary artery disease. *Am Heart J*. 1996;131:440-50.
28. Shivalkar B, Flameng W, Szilard M, Pislaru S, Borgers M, Vanhaecke J. Repeated stunning precedes myocardial hibernation in progressive multiple coronary artery obstruction. *J Am Coll Cardiol*. 1999;34:2126-36.
29. Chachques JC, Haab F, Cron C, Cabrera Fischer E, Grandjean P, Bruneval P, et al. Long-term effects of dynamic aortomyoplasty. *Ann Thorac Surg*. 1994;58:128-34.
30. Delrossi AJ, Cernaianu AC, Vertrees RA, Ciley JH Jr, Baldino WA, Camishion RC. Biotransformation of skeletal muscle used for long-term dynamic aortomyoplasty. *Basic Appl Myol*. 1991;4:311-6.

## Discussion

**Dr George L. Hicks, Jr (Rochester, NY).** This was an elegant long-term study. Clearly, in a chronically ischemic model you need to increase diastolic flow while you are treating heart failure by decreasing cardiac work. So what were your results in terms of the left ventricular dynamics?

**Dr Hedayati.** Although the data were not presented, we did measure load-independent and load-dependent variables of cardiac performance with a conductance catheter that measured ventricular volume. Values such as contractility, stroke work, preload recruitable stroke work, and afterload did improve during counterpulsation, with some of the values reaching statistical significance. These are discussed at length in our manuscript.

**Dr Ernst Wolner (Vienna, Austria).** I have two comments. Number one, usually patients who use such a device have a calcified and inflexible aorta. That is why we use fresh homografts and a large pericardial patch to obtain similar results.

Number two, in the early 1970s, as balloon pumping came up, I had used at that time (before the transplant era) in some patients so-called long-term balloon pumping in cardiomyopathy, where we implanted the balloon pump over the iliac artery and had it tunneled under the skin. The long-term effect of this treatment at that time was more or less inefficient, so I have some concern that you can assist patients with cardiomyopathy with such a device. However, it is an elegant study.

**Dr Hedayati.** Aortic calcification is a contraindication to aortomyoplasty. With respect to your second comment, our study was based on an ischemic heart failure model in which we compared aortomyoplasty with the IABP, which has been the criterion standard of diastolic counterpulsation. Currently, diastolic augmentation is achieved with lower extremity external compression devices in patients with unstable angina, and this has been effective long-term in clinical practice.

**Dr Paul Kurlansky (Miami Beach, Fla).** I congratulate you on an interesting study. I note that from the enhanced external counterpulsation literature we find that 35 weeks of treatment with external counterpulsation can result in increased myocardial perfusion and actually symptomatic benefit that will last 3 years after therapy has stopped. I was just wondering whether you have any long-term experiments which show changes in myocardial perfusion.

**Dr Hedayati.** The aortomyoplasty procedure and subsequent muscle stimulation and conditioning were performed during the year before the acute studies. Our long-term plans would be to show the effects of chronic aortomyoplasty counterpulsation and to examine the effects on the myocardium with tests such as stress echocardiography.